

Really Straight Teeth™



Volume 5, Issue 1

Adult & Child Braces and Early
Interceptive Treatment for Ages
6-9
(©Fox 2016)

Inside this Issue

- 1 I did not know
- 1 Class II Test, to tell if you need to send at age 7 or not
- 2 Class III Test, to tell if you need to send at age 7 or not
- 3 "Is there enough space for all the permanent teeth to erupt?" Test
- 3 Special Note
- 3 Summary
- 3 About Dr. Fox and his office
- 4 Important Note

Donald M. Fox, D.D.S., M.S.

©2016 Fox

“Tests to Tell” Whether To Send A Child At Age 7 or Not!

*Donald M. Fox, D.D.S., M.S.
Diplomate of the American Board of
Orthodontics*

“I did not know”:

This is the most common phrase heard from parents bringing children in at age 10-12 when problems existed at age 7 that could have been detected and treated.

Children today are maturing so much sooner and faster, especially girls. Over 25% of girls seen today at the age of 9 have already lost their primary teeth and most of them have their 2nd molars erupting. So, it is even more important to detect problems early such as space problems or jaw growth problems.

Parents appreciate your concern that you are looking out for the best interest of their child to have them looked at by someone who knows facial growth and that has an arsenal of tools to treat any problem that exists.

Dr. Fox not only has training to handle early treatment problems; he has a Master’s of Science degree in Dentofacial Orthopedics. Many orthodontists in the United States only have a certificate in Orthodontics. Also, to become a Diplomate of the American

Board of Orthodontics, Dr. Fox had to demonstrate competence in the early interceptive treatment of 7 years olds. For that matter, most of the testing and diagnosis of cases to become Board Certified in 1993 was early treatment cases.

So, when you refer a patient for early treatment problems, you do have the empowerment to tell the patient to go see an orthodontist. But, you also have the power to tell a patient to seek care with an orthodontist that can handle any early treatment problem and they will go there, no matter how far the distance.

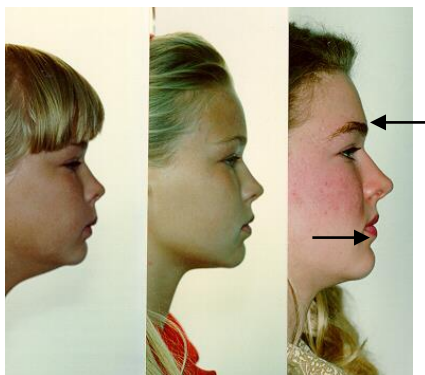
Children sometimes exhibit early signs of jaw problems as they grow and develop. An upper and lower jaw that is growing too much or not enough can be recognized at an early age. If children **after age 6** are found to have this jaw discrepancy, they are candidates for early orthodontic treatment. It is encouraged to have all children seen at age 7 on their birthday to make sure nothing is truly wrong. Not doing so can leave a child’s smile and profile compromised later.

Class II Test, to tell if you need to send at age 7 or not:

A 7-year-old child is in your chair for a routine exam and cleaning. They appear to have a severe overjet. Should I send the child now to the orthodontist? The answer is always yes because an overjet is always classic for jaw growth problems. Minimally, if the lower jaw is not retruded, the upper front teeth should be retracted to prevent the child from fracturing their incisors.



The next child you see at their exam has a 4.0 mm. overjet, but it is hard to tell if the lower jaw is retruded. The test to tell if they have a retruded lower jaw is simple. Sit the child up and have their back away from the chair. Have them look at a point on the wall. Look at their chin area from the side. If the crease under the lower lip does not stick out as far as their forehead point right above their eyebrows, there is a problem.



Another test is to have the child hold their incisors end-to-end and look at their profile from the side. If their profile now looks better, you have a lower retruded jaw on your hands. On the other hand, if they now look like Jay Leno, the problem probably is limited to their teeth.

The next child is now in your chair and there is no overjet. But, the child seems to have a retruded lower jaw profile or a “no chin” appearance. What usually is going on with this child is that there is a retruded lower jaw. But, all of the lower teeth have shifted forward on the lower arch of bone giving you a “fake Class I molar” appearance.

Class III test to tell if you need to send at age 7 or not:

The Class III at age 7 case is the hardest one to diagnose and the easiest one to ignore and not send for early

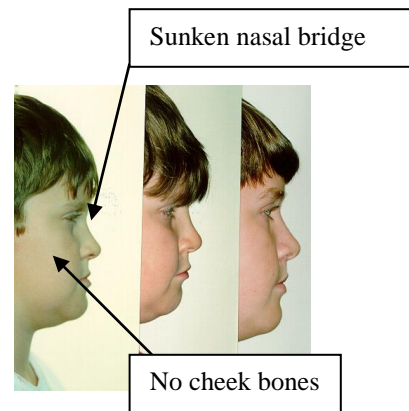
interceptive treatment. The reason it is so easy to ignore is that in dental school one is taught that all Class III cases are not treated until the age 16 and it usually requires jaw surgery to set back the lower jaw. Today, in Florida, more than 70% of patients seen are upper jaw retrusion cases that are 100% correctable at age 7. To not refer an upper retruded Class III case at age 7 sets up the patient to have upper jaw surgery later when it could have been totally avoided. The upper jaw can be made to grow as much as a half inch!

The test to tell if the upper jaw is part of the problem or not is rather simple. If the patient has a bulldog bite, sit them up in the chair with their back away from the chair. Have them look at a point on the wall. The crease under their lower lip should not stick further out than their forehead point just above their eyebrows. If it does, the lower jaw is probably growing too much. The problem is not over yet. An orthodontist with complete early treatment training should still see this child to take a lateral cephalogram x-ray to document and monitor the jaw growth.

The reason for this is that there are computers at Dr. Fox’s office that trace this x-ray. Future tracings can then be overlaid on the computer to see the amount of growth of the maligned bones over time. The lower jaw can be surgically set back only when x-rays have confirmed that the lower jaw has stopped growing. It is sad to see a patient come in at 16 and then we have to wait to confirm that the lower jaw has stopped growing before surgery can be performed.

Now, you have another child in your chair and they have a bulldog bite. You sit them up in the chair and you do the above test. The lower jaw is in line with the upper forehead, but stepping

back you notice that their entire mid-face looks sort of sunken in. The child has no cheek bones and their nasal bridge just below the eyebrows looks sort of caved in or not out as far as it should be. You have just found a Class III upper retruded jaw case!



The next child you look at in your chair at their exam seems to have one or both of the above Class III test features but they do not have a bulldog bite. Look close and you will find that Mother Nature has been compensating for the Class III bone problems. The upper incisors are tipped forward and the lower incisors are tipped lingually. Again, many of these types still must be treated at age 7 to bring the upper jaw forward with growth. This will cause an overjet to exist, which gets corrected by retracting the upper incisors to their normal position in the maxilla.

Well, you go and say so what? The child’s teeth look okay, why do any treatment to this last child? The parents say the same thing. But, many of these cases will grow worse over time and when they come in at age 9-10 it is now too late. The other reason is that when braces are placed on a case as this type at age 12 to correct crowding, it becomes difficult to control the teeth. The simplest way to explain what is being said here by “control” is the fact that once an orthodontist places braces on a child or an adult, an amazing thing

occurs. The teeth tend to want to go where they naturally want to be in the bone structures.

So, later at age 12, a Class III bone problem with no bulldog bite gets their braces placed on to correct some crowding and what pops up months later is a bulldog bite! This is from the upper teeth tipped back and the lower teeth tipped out to their natural positions in the bones when the braces were placed. But, now this gives a bulldog bite requiring jaw surgery to correct the bite.

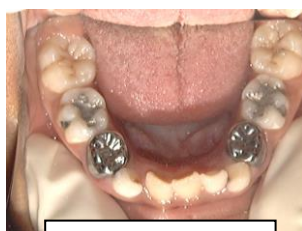A side comment is given here. Many cases that do come in that are Class III today at age 12 and never had early treatment need their dental compensations removed. To wait for the age of 16 to place their first braces on to set them up for jaw surgery can be damaging. The lower incisors in most of these cases need to be tipped forward at the age when the cortical plates are flexible and pliable. Yes, there is still a slight chance that gum recession can occur on these patients, but not as near the chance if you wait until age 16 where the cortical plates are very hard and not willing to give.

“Is there enough space for all the permanent teeth to erupt?” Test:

It is amazing what the power of simplicity does for someone. Keep it simple when looking at space for permanent teeth to erupt. Just take a look and ask yourself, “if the canines come in and they are twice the size of the primary canines, will they fit?” If not, early interceptive treatment is needed.

Parents should be shown their children’s mouth at age 7 in the following fashion if space problems exist. They are shown the lower anterior teeth. They

are told that space usually exists between the lower incisors so that when the large canines come in they push all that space closed. Now, if there is no space present, we ask the parents, “what do you think is going to occur when the canines come in?” The parents always state that the canines will crowd things up. Then, we ask, “if the lower incisors are already crowded, what do you think will occur when the canines erupt?” The parents always state we need to make more room for the canines.



#26 is impacted

Doing a Bolton Index and all of the other tests in dental school to measure eruption space are useful, but not practical in the clinical sitting for a general dentist. The key is the canines. The premolars are of no relevance since they are smaller than the primary teeth above them.

There is one more test overlooked by even most orthodontists. So, you are looking at another child and it is hard to tell if all the teeth are going to fit. The child appears to have slight to moderate crowding. The test done is the Hamular notch test. If the distance between the distal of the upper 1st molar and Hamular notch does not look like it will accommodate a 2nd molar you may well have a space problem. This is what we in Orthodontics call an “arch length” problem. The arch is just not long enough to accommodate all the teeth.

The arch does get longer in that area over time, but in most children it does not. On top of that, you still have to have room for the 3rd molars!

Special note:

The American Association of Orthodontists recommends that a child’s first visit to an orthodontist be at age 7. Often children within a family will exhibit certain predictable patterns of growth in much the same way they inherit similar eye and hair color. Like other family traits, particular patterns of tooth and jaw development also “run in the family.”

With these facts in mind, it is hoped that all children are examined at age 7. The only other way to detect maligned jaws is with a lateral cephalogram x-ray.

Summary

It is hard sometimes to convince a parent to take their child to have them checked out for early interceptive treatment. The only thing you can do is be firm and let them know you care about their child’s dental health. The power a general dentist has in referring a patient for early intervention is very strong. Most patients will travel even 20 miles to an orthodontist if the general dentist tells them “this is where you should go” because your patients trust you. Also, that great feeling you will get, knowing that the patient is getting the best care is priceless.

About Dr. Fox and his office

Dr. Fox has treated hundreds of early treatment cases in 27 years including cleft lip and palate cases. He has treated over 8,000 adult and child cases.

.

.

Important Note

The general practitioner is in an excellent position to detect, intercept and correct minor orthodontic problems early, thus making it unnecessary for the child to go through complex orthodontic treatment at a later date. Most patients who have Phase I early treatment usually only have 12-18 months of simple Phase II teenage braces. 5-10% never needs Phase II. Getting the child in at age 6-7 is ideal; after age 10, we're lucky if prevention can be accomplished; and referrals that come after age 10 come too late for prevention or early treatment interception.

REALLY STRAIGHT TEETH is published for the dental community as an educational service. For further information on any of these services, contact:

DONALD M. FOX, D.D.S., M.S.
Adult & Child Braces and
Early Interceptive Treatment
For Ages 6-11

Diplomate: American Board of
Orthodontics
Member: American Association
of Orthodontists
Recognized: Who's Who in
America
Recipient: Harry Sicher
Research Award of the
American Association of
Orthodontists
Member: Broward County
Dental Association

