

# Really Straight Teeth

© 2016 Fox

South Florida's Full Service Orthodontist

Volume 1, Issue 3

Adult & Child Braces and Early Interceptive Treatment for Ages 6-11

## Inside this Issue

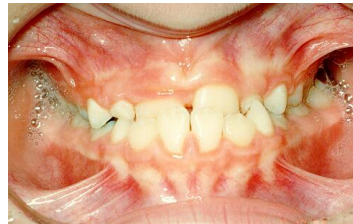
- 1 Class III Bite Treatment (ages 7-8)
- 1 What causes Class III bites?
- 2 Can Class III bites be prevented or kept from worsening?
- 2 Can a Class III bite be treated in the age group of 6-8 years?
- 3 Summary
- 3 About Dr. Fox
- 3 Important Note

Donald M. Fox, D.D.S., M.S., P.A.  
255 SE 14th Street  
Ft Lauderdale, Florida 33316  
(954) 523-6525

## Early Interceptive Class III Treatment

Donald M. Fox, D.D.S., M.S.  
Diplomate of The American Board of Orthodontics

The so-called “bulldog” bite is one of the most unrecognized and misdiagnosed in the dental profession.



Interestingly, most Class III bites I have seen in private practice in 11 years are not true lower jaw protrusion but actually upper jaw retrusion. In many cases that do have true lower jaw protrusion, the upper jaw is also retruded requiring early interceptive treatment.

The following areas will be discussed:

- 1) What causes Class III bites?
- 2) Can Class III bites be prevented or kept from worsening?
- 3) Can a Class III bite be treated in the age group of 6-8 years?

## #1: What causes Class III bites?

The subject of what causes Class III bites has to do mainly with the areas of genetics, before birth development and

occlusal interferences. Many Class III problems “run in the family” and have been traced all the way up the family tree. Another cause of upper jaw retrusion has been seen on ultrasound where the child before birth placed their forearm across their midface while in the womb.

Another cause is the pseudo-Class III where the upper incisors are tipped slightly palatally. This causes enough occlusal interference to make the child (as early as 6 years old) to shift their lower jaw forward to a more “comfortable” bite. But, left alone, this acts theoretically as functional treatment, causing the lower jaw to grow too far forward.

These pseudo-Class III's are tricky to diagnose and never should be underestimated. Treating the front teeth with pop-sickle sticks to move the teeth out of crossbite can be dangerous if not diagnosed fully to rule out jaw alignment problems of the upper and/or lower jaw(s).

The only true way to diagnose a Class III bite is with a lateral cephalometric X-ray and tracing the film and measuring the bony structures. In my office, this is no longer a timely ordeal since with computers, the X-ray is traced and up to 20 cephalometric analyses are done within 6 minutes. The computers also allow me to actually simulate treatment by moving the teeth and jaw(s) to see what the final result will look like.



## #2: Can Class III bites be prevented or kept from worsening?

The second question deals with the early detection and referral of any patient who has any jaw alignment problem, anterior or posterior crossbites and where centric relation does not equal centric occlusion. This should be at age 7 or earlier if the problem is noticed before age 7.

Lower jaw protrusion from “too much growth” is not preventable. There have been attempts to prevent lower jaw growth with everything from an ace bandage wrapped around the head to a device used in Scoliosis orthopedic treatments called a Milwaukee Brace.

This large contraption actually was found to be linked to a high incidence of TMJ from its distal pressure it placed on the lower jaw that took its toll on the temporomandibular joint. Overall, trying to stop lower jaw growth would be the equivalent of someone trying to stop Shaq O’Neal (Los Angeles basketball player) from growing tall when he was a teenager.

Lower jaw protrusion can be prevented if it’s a pseudo-Class III bite by treating with special types of retainers in conjunction with partial braces. Results can be seen in as quickly as 6 months and others in 12 months.

## #3: Can a Class III bite be treated in the age group of 6-8 years?

The third historical issue dealing with early treatment deals with what we call “orthopedics”. Orthopedics is skeletal correction via growth alteration.

The Class III has to be diagnosed properly to see if upper jaw retrusion is the cause of the problem, which in many of the cases it is. But, upper jaw retrusion is difficult to see with the naked eye or without a lateral cephalometric X-ray. All Class III patients must have a cephalometric X-ray at their first orthodontic exam to truly diagnose this. Telling a parent of a Class III child at the first orthodontic exam “that it appears okay” and we need to wait” without first taking this X-ray will only set one up for trouble later on when it is found that the upper jaw was actually retruded.

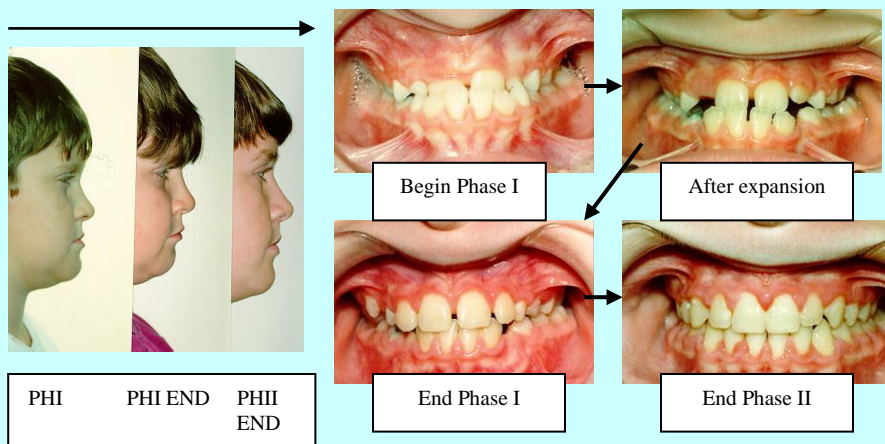
I have in my practice seen over and over a patient who has been told to wait to treat their Class III. They were told that nothing could be done until after age 13 or 15 when the lower jaw has stopped growing. Then the parent is told the alarming fact that it is actually the upper jaw and that upper jaw surgery (not the lower) is needed and it could have been prevented if diagnosed and treated early at age 7.

Then there is the patient who in actual fact does have lower jaw protrusion but also has upper jaw retrusion and was improperly told no treatment was needed. Now the patient is committed to double jaw surgery when it should have only been lower jaw surgery. The patient could have been treated early to bring the upper jaw forward.

The early treatment of a child at age 7 with a Class III bite is simple to understand. The upper jaw is really a two-bone structure separated by cartilage down the middle of the mouth. The upper jaw is also attached to the zygomatic arches, the nasal bridge area

### Example of a Early Treatment Class III Bite Case

The below patient had a severe upper jaw retrusion and a severe narrow upper arch. Notice the chin button is directly in line with the forehead, which indicates the entire midface, is “sunken-in”. Upper expansion was done first to expand and loosen “all” cartilage sutures. Then with only 5 month’s use of a reverse-pull facemask, the entire midface (nose, bridge of nose, zygomatic arches, cheekbones and maxilla) were brought forward. Later, full braces were placed in Phase II for only 12 months to obtain a result without jaw surgery or extractions.



and the base of the skull with cartilage. But, starting at the age of 10, the cartilage starts to turn into bone making upper jaw growth difficult to do.

It is this cartilage that needs to be first addressed in treatment at age 7. To make the upper jaw grow forward, one must make this cartilage very loose and rubbery. This is best done with expansion devices. So, Class III treatment must start early to prepare for the upper jaw to be pulled forward.

Interestingly, most upper jaw retrusion cases need expansion. This is because the upper jaw is deficient in many dimensions. It is short front to back, narrow across the arch and is located along with the rest of the whole midface in a "sunken-in" position (called maxillary hypoplasia). Even though upper jaw growth treatment works, many of these patients will require an upper only serial extraction. This is because during treatment the upper jaw and midface are pulled forward, but the arch length (length of the upper jaw from the incisors back to the hamular notch) is not increased or improved. Therefore, no extra space is gained to fit all the upper teeth into the arch by this technique.

The upper jaw, when ready to be pulled forward, is best done with a reverse-pull facemask that hooks via elastics to the upper first molars which are banded. The child is told the facemask is basically a "catcher's mask" and that the forehead and chin are used to pull the upper midface forward. It is worn mainly to bed and is easily placed on within 30 seconds.

It usually causes no discomfort and results are seen as quickly as 2 months for simple cases and in 6 months for severe cases. It has over a 90% success rate if started at age 6-8. After age 10, the prognosis is poor, but results have been obtained in my office after age 10.

## Summary

The hardest thing to tell a mother of a teenager who comes into the office is that many of the problems her child has needed to be handled at an earlier age and now the case requires extensive braces and jaw surgery to treat the Class III bite. So, if there is any doubt that a patient should have an orthodontic exam early (as recommended by the American Association of Orthodontists at age 7) it would be best to have the child seen early to provide the best future for the child dentally and economically.

## About Dr. Fox

After dental school, many orthodontists receive what is called a "certificate" in orthodontics. Beyond a certificate program is a Master's degree program involving extensive literature study and research and writing of a Master's thesis. Dr. Fox actually has a Master's degree in Orthodontics and Dentofacial Orthopedics (early interceptive treatment). He has trained under many clinicians that are leaders in facial growth that have developed appliances for jaw growth. Many treatments no longer require the use of bulky plastic appliances (as Bionators, Herbst, etc.) and now are replaced with special coils and elastics hooked to braces on the incisors and 1<sup>st</sup> molars.

## Important Note

The general practitioner is in an excellent position to detect, intercept and correct minor orthodontic problems early, thus making it unnecessary for the child to go through complex orthodontic treatment at a later date. Most patients who have Phase I early treatment usually only have 12-18 months of simple Phase II teenage braces. 5-10% never need Phase II. Getting the child in at age 6-7 is ideal; after age 10, we're lucky if prevention can be accomplished; and referrals that come after age 10 come too late for prevention or early treatment interception.

**REALLY STRAIGHT TEETH is published for the dental community as an educational service. For further information on any of these services, contact:**

**DONALD M. FOX, D.D.S., M.S.**  
Adult & Child Braces and Early Interceptive Treatment For Ages 6-11

Diplomate: American Board of Orthodontics  
Member: American Association of Orthodontists  
Recognized: Who's Who in America  
Recipient: Harry Sicher Research Award of the American Association of Orthodontists  
Member: Broward County Dental Association

.....